

Congenital Panfollicular Nevus

Rezaei M¹, Mohaghegh F^{2*}, Malakoutikhah Z³ and Nikyar Z⁴

¹Medical doctor, school of medicine, Isfahan University of Medical Sciences, Isfahan, Iran

²Professor of dermatology, Department of dermatology, Isfahan University of Medical Sciences, Isfahan, Iran

³Resident of dermatology, Department of dermatology, Isfahan University of Medical Sciences, Isfahan, Iran

⁴Dermatologist, Department of dermatology, Razi hospital, Tehran University of Medical Sciences, Tehran, Iran

*Corresponding author:

Fatemeh Mohaghegh,
Professor of dermatology, department of
dermatology, Isfahan University of Medical
Sciences, Isfahan, Iran, Tel: +989133050219;
E-mail: F.mohaghegh@med.mui.ac.ir

Received: 02 Feb 2022

Accepted: 15 Feb 2022

Published: 19 Feb 2022

J Short Name: ACMCR

Copyright:

©2022 Mohaghegh F. This is an open access article distributed under the terms of the Creative Commons Attribution License, which permits unrestricted use, distribution, and build upon your work non-commercially.

Citation:

Mohaghegh F, Congenital Panfollicular Nevus. Ann Clin Med Case Rep. 2022; V8(10): 1-4

Keywords:

Congenital nevus; Follicular nevus; Nevus

1. Abstract

A 1-month-old girl presented to our dermatology clinic with a few irregular asymptomatic nodules on her scalp which were present at birth and had recently increased in size. An incisional biopsy was taken, and the results were compatible with a newly proposed entity called congenital panfollicular nevus.

2. Introduction

Cutaneous adnexal tumors are a wide spectrum of morphological changes in different appendage structures present on the normal skin. Many of these lesions are benign and occur in the head and neck region (1). Although many of these lesions do not have malignant potentials, they may have significant psychosocial effects. Congenital panfollicular nevus (CPN) is a hair related hamartoma which is characterized by a well-circumscribed lesion containing aberrantly differentiated clustered hair follicles in high density (4). Here we report a case of CPN in a 1-month-old girl.

3. Case Report

An otherwise healthy 1-month-old female newborn was brought to our dermatology clinic by her concerned parents regarding a skin lesion on her scalp. The infant was born through an elective

caesarean section due to transverse lie at 38 weeks of pregnancy. Her mother noticed a small lesion on her scalp at birth and following a slight increase in the size of the lesion, she brought the infant in for further assessments. On physical examination, there was a 0.5×0.6×0.3 cm pink to yellow lesion on the frontal part of her scalp that was composed of a few smaller non-tender smooth nodules (Figure-1). Except for the mentioned lesion, physical examination was completely normal. There was no family history of birthmarks or other skin lesions and no drugs had been applied on the lesion. An incisional skin biopsy was planned for the patient and histopathology revealed normal epidermis without papillomatosis. In the dermis layer, there were some aggregated abortive hair follicles surrounded by a fibrous sheath. No normal hair follicle was identified and there was no abnormal eccrine or apocrine gland (Figure 2- a,b,c). These histopathologic findings were compatible with congenital panfollicular nevus. A wait-and-see approach was taken for this patient to observe and evaluate the lesion in terms of growth and morphological changes. At the follow up visit six months and one year later, the lesion was examined and there was no evidence regarding growth or morphological changes (Figure 3).

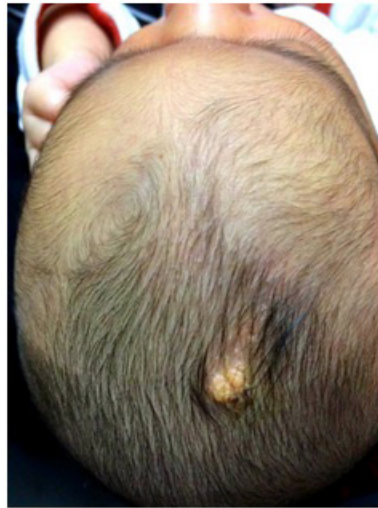

Figure 1: Panfollicular nevus of the scalp

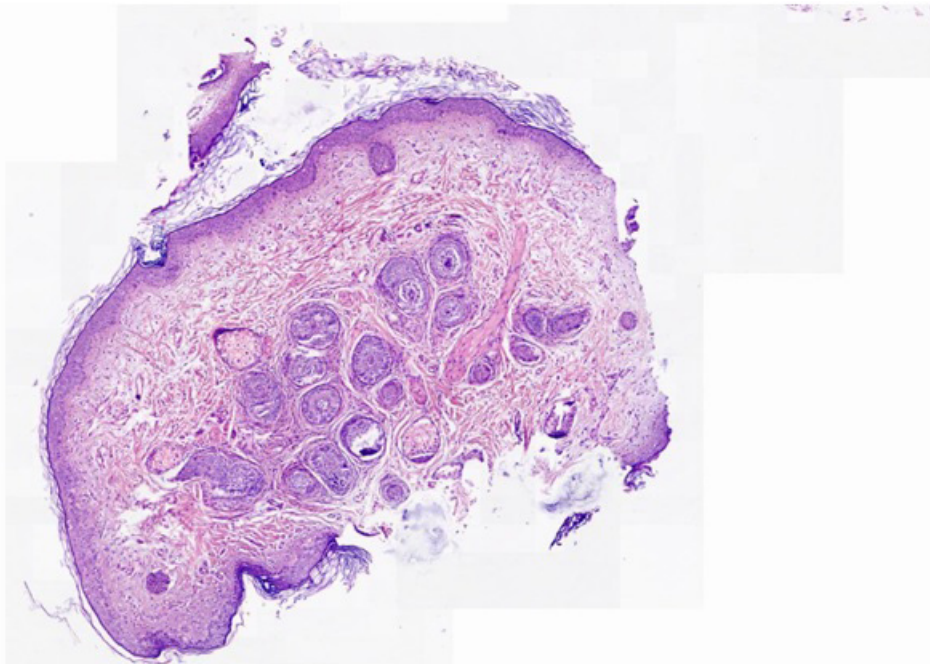


Figure 2-a: Normal epidermis without papillomatosis, aggregated abortive hair follicles surrounded by a fibrous sheath (H&E×40).

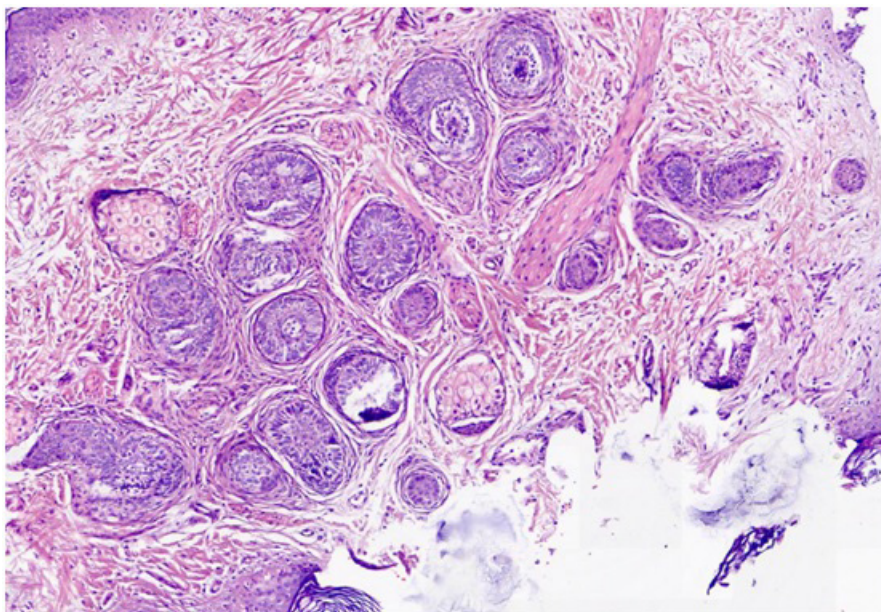


Figure 2-b: Normal epidermis without papillomatosis, aggregated abortive hair follicles surrounded by a fibrous sheath (H&E×100)
<http://acmcasereports.com>

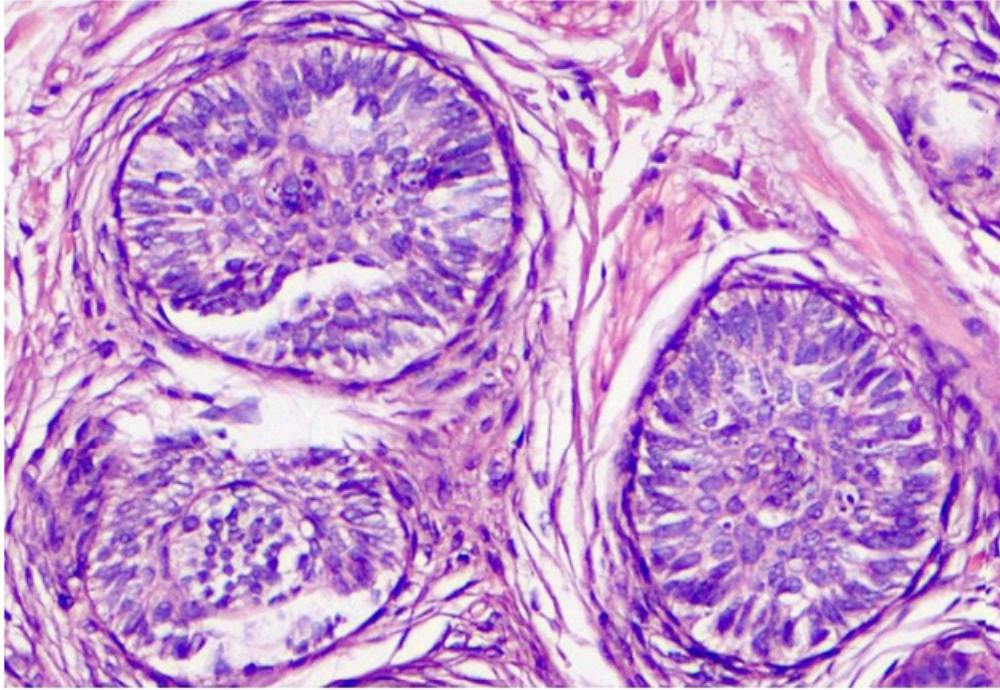


Figure 2-c: Normal epidermis without papillomatosis, aggregated abortive hair follicles surrounded by a fibrous sheath (H&E×400).

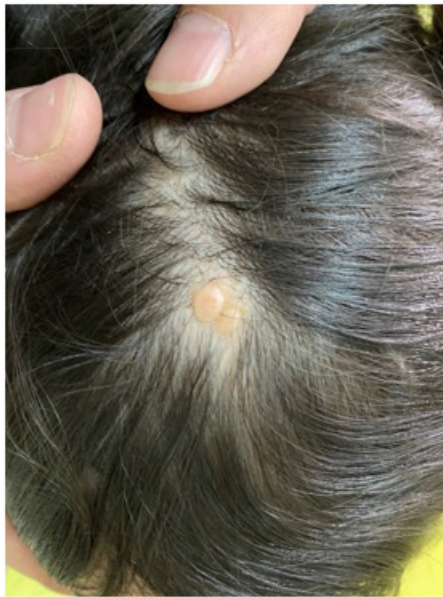

Figure 3: Lesion at the follow up visit.

4. Discussion

Hair follicle hamartomas are rare, benign and often congenital lesions of the head and neck that present a small nodule or area of hypertrichosis which are consisted of hair follicles in different stages of proliferation (2).

Congenital panfullicar nevus (CPN) was first described by Finn et al. in 2005 as a nodular lesion that contained hair follicles in different stages of proliferation from akin to normal terminal hair which were not associated with any genodermatous syndrome or other adnexal neoplasm (3). They are described as large, elevated, well circumscribed, pink-tan, multinodular, non-ulcerative skin lesions on the neck, scalp or hands which may enlarge in time. There are a few case reports of CPN in the current literature (3-6). Finn and <http://acmcasereports.com>

Argenyi reported a case of a congenital nodule which was primarily considered a syringocystoadenomappiliferum based on its clinical presentation but the histopathologic findings following an excisional biopsy revealed multiple dermal nodules that contained abortive hair follicles that were surrounded by fibrous sheaths. This case report led to introducing this new entity (3). Kim J et al. reported a case of asymptomatic pink-tan cutaneous papules on the first and second ray of the left hand and wrist. Histopathology revealed an abortive attempt at hair follicle formation. This case of CPN was associated by distal polydactyly of the left thumb and syndactyly of the first web space that suggested a possible connection between limb patterning and hair follicle development (4). Also, Duan et al. reported an irregular nodule on the right lateral

neck in a 6-month-old girl which was present at birth but had been growing. The lesion was excised by surgery and the microscopic findings were compatible with CPN (6).

An important differential diagnosis for CPN is the nevus sebaceous of Jadassohn. It is a congenital lesion in approximately 0.3% of newborns that may contain any skin component including sebaceous and apocrine gland and hair follicles. In the early infancy it presents as a smooth well-circumscribed plaque and is classically located on the vertex of the head but can also be seen on the face and neck. During puberty, hormonal changes lead to proliferation of the lesion and they can turn into benign or malignant tumors later in life (7-9).

Our case met the clinical and histopathologic criteria of CPN. The significant point in this case report was the increase in the size of the lesion over the first few months which could be suspicious for malignancy. In these cases, the patient should be followed thoroughly, and skin biopsy is also recommended.

References

1. Ireland AM, Harvey NT, Berry BD, Wood BA. Paediatric cutaneous adnexal tumours: a study of 559 cases. *Pathology*. 2017 Jan; 49(1): 50-54. doi: 10.1016/j.pathol.2016.10.003. Epub 2016 Nov 30. PMID: 27914683.
2. Davis DA, Cohen PR. Hair follicle nevus: case report and review of the literature. *Pediatr Dermatol*. 1996 Mar-Apr; 13(2): 135-8. doi: 10.1111/j.1525-1470.1996.tb01420.x. PMID: 9122071.
3. Finn LS, Argenyi ZB. Congenital panfollicular nevus: report of a new entity. *J Cutan Pathol*. 2005 Jan; 32(1): 59-62. doi: 10.1111/j.0303-6987.2005.00257.x. PMID: 15660657.
4. Kim J, Zambrano EV, McNiff JM. Congenital panfollicular nevus associated with polydactyly. *J Cutan Pathol*. 2007 Dec; 34 Suppl 1: 14-7. doi: 10.1111/j.1600-0560.2006.00714.x. PMID: 17997731.
5. Shiba K, Yanagi T, Nakazato S, Imafuku K, Kitamura S, Hata H, Shimizu H. Case of congenital panfollicular nevus with remarkable adipose tissue proliferation. *J Dermatol*. 2017 Apr; 44(4): e77-e78. doi: 10.1111/1346-8138.13653. Epub 2016 Oct 28. PMID: 27790746.
6. Duan L, Antaya RJ, Ko CJ, Narayan D. Congenital Panfollicular Nevus in a 6-Month-Old Girl. *Pediatr Dermatol*. 2016 Mar-Apr; 33(2): e137-9. doi: 10.1111/pde.12771. Epub 2016 Jan 29. PMID: 26822169.
7. Benjamin LT. Birthmarks of medical significance in the neonate. *Semin Perinatol*. 2013 Feb; 37(1):16-9. doi: 10.1053/j.semperi.2012.11.007. PMID: 23419758.
8. Groesser L, Herschberger E, Ruetten A, Ruivenkamp C, Lopriore E, Zutt M, et al. Postzygotic HRAS and KRAS mutations cause nevus sebaceous and Schimmelpenning syndrome. *Nat Genet*. 2012 Jun 10; 44(7):783-7. doi: 10.1038/ng.2316. PMID: 22683711.
9. Idriss MH, Elston DM. Secondary neoplasms associated with nevus sebaceous of Jadassohn: a study of 707 cases. *J Am Acad Dermatol*. 2014 Feb; 70(2):332-7. doi: 10.1016/j.jaad.2013.10.004. Epub 2013 Nov 20. PMID: 24268309.