

Persistence HFRS Infection Risk Among Migrant Outdoor Labours in Shanghai, China: A Case Report

Ai-Qin Zhu^{1,2}, Hong-Mei Xu¹, Chu-Chu Ye¹, Han-Zhao Liu¹, Yi-Yu Jin¹, Li-Peng Hao¹, Xiu-Hong Chen¹, Wei-Ping Zhu¹ and Yi-Xin Zhou¹

¹Division of Infectious Disease Prevention and Disinfection Management, Shanghai Pudong New Area Center for Disease Control and Prevention, Shanghai, China

²Shanghai Mental Health Center, Shanghai Jiaotong University School of Medicine, Shanghai, China

*Corresponding author:

Wei-Ping Zhu and Yi-Xin Zhou,
Shanghai Pudong New Area Center for Disease
Control and Prevention, No. 3039 Zhangyang Road,
Pudong New Area, Shanghai 200136, China,
E-mail: junnybaby@126.com and
18930733119@163.com

Received: 18 May 2022

Accepted: 01 Jun 2022

Published: 05 Jun 2022

J Short Name: ACMCR

Copyright:

©2022 Wei-Ping Zhu and Yi-Xin Zhou. This is an open access article distributed under the terms of the Creative Commons Attribution License, which permits unrestricted use, distribution, and build upon your work non-commercially.

Citation:

Wei-Ping Zhu and Yi-Xin Zhou, Persistence HFRS Infection Risk Among Migrant Outdoor Labours in Shanghai, China: A Case Report. *Ann Clin Med Case Rep.* 2022; V9(6): 1-3

Keywords:

Hemorrhagic fever with renal syndrome; Death case; Migrant outdoor labours; Epidemiology

Abbreviations:

HFRS: Hemorrhagic Fever with Renal Syndrome; CDC: Center for Disease Control and Prevention

1. Abstract

Background

Hemorrhagic fever with renal syndrome (HFRS), a rodent-borne disease caused by hantaviruses, is clinically characterized by fever, circulatory collapse with hypotension, hemorrhage, and acute kidney injury. China has the largest number of HFRS cases worldwide, with outbreaks occurring in both eastern coastal cities and inland cities, occasionally resulting in death, it is necessary to find loopholes in prevention and control measures to reduce the occurrence of such infectious diseases.

Case Presentation

A 52-year-old Chinese male construction worker presented with persistent fever, weakness and deficiency, diarrhea, and cough. Two days after being admitted to the hospital, he died due to rapid progression of the disease, which was eventually diagnosed as HFRS.

Conclusions

To prevent outbreaks of vector-borne diseases in cities, it is necessary to strengthen environmental health management in areas prone to the proliferation of rats and other disease vectors, such as urban-rural junctions, where gathering a lot of migrant outdoor labours, to eliminate potential risk factors.

<http://www.acmcasereports.com/>

2. Background

Hemorrhagic fever with renal syndrome (HFRS) is a natural infectious disease caused by hantaviruses in the order Bunyavirales. It has the characteristics of rapid onset, a wide distribution, serious morbidity and high mortality. Approximately 150,000 to 200,000 patients with HFRS are hospitalized worldwide each year [1]. China has the largest number of HFRS cases in the world and large epidemic area [2,3]. Some coastal cities in China have been endemic for HFRS for a long time [4-6], and a death due to HFRS was reported in Shanghai Pudong New Area in March 2021; this was the second death caused by HFRS reported in the past decade. The previous death occurred in 2012. This prompted our investigation and emphasizes the need for prevention and control strategies. This study reports the case of an individual who died due to HFRS to provide a reference for the prevention and control of HFRS.

4. Case Presentation

A 52-year-old Chinese man who was a construction worker was admitted to the hospital with fever for 7 days and diarrhea and cough for 3 days on March 24, 2021. In the early morning of March 17, 2021, the patient developed fever without obvious inducement. His body temperature was 40°C, and he reported fatigue, but he had no other symptoms and did not seek medical treatment. On

March 21, the patient developed watery diarrhea accompanied by cough but still did not seek medical treatment. The patient did not visit the local hospital for treatment until the 23, and he presented with multiple organ failure on admission. On the 24, the patient was transferred to a hospital downtown for treatment. His vital signs were as follows: body temperature 36.3°C, heart rate 119/min, respiratory rate 25/min and blood pressure 69/48 mmHg. A physical examination revealed petechiae on the trunk and limbs, variegation on the skin of the whole body, edema and congestion in the conjunctiva of the eyes, and coagulation in the mouth. On admission, hematologic tests revealed the following: C-reactive protein 17.96 mg/L, leukocyte count $26.8 \times 10^9/L$, hemoglobin 190 g/L, platelet count $11.0 \times 10^9/L$, lymphocyte count $6.5 \times 10^9/L$, and neutrophil count $15.3 \times 10^9/L$. The prothrombin time was 14.9 s, and the partial thromboplastin time was 99.2 s; the thrombin time could not be detected. Fibrinogen was 2.065 g/L, and D-dimer was 5.62 mg/L. Liver and kidney function examinations showed the following: total protein 49 g/L, albumin 23 g/L, alanine transaminase 377 U/L, glutamic oxaloacetic transaminase 804 U/L, urea 22.1 mmol/L, and creatinine 364 mol/L. Chest and abdomen computed tomography scans showed multiple small nodules in both lungs, multiple exudations around both kidneys, abdominal effusion, and bilateral paracolic sulcus effusion. Based on these re-

sults and the results of the physical examination, he was clinically diagnosed with sepsis, septic shock, suspected HFRS, metabolic acidosis, multiple organ dysfunction, thrombocytopenia, and coagulation dysfunction. After admission, the patient's condition deteriorated rapidly. At 23:00 on March 24, an enzyme-linked immunosorbent assay revealed that the patient was positive for IgM antibodies against HFRS, while IgG was negative. Unfortunately, the patient died in the early morning of the 25, and at 08:00 on the 25, the laboratory test result came back positive for hantavirus nucleic acid (Figure 1). After the patient died, we investigated the conditions around the patient's residence. He lived in a container on a construction site located in the urban-rural fringe area, and rats were often seen in the container. We captured 5 *Apodemus agrarius* in the vicinity of the decedent's residence. The density of the mice was 4.6 per 100 clips. One of the mice tested positive for hantavirus nucleic acid (the ct values of the mouse lung and liver specimens were 22.85 and 34.73, respectively). Moreover, we collected 462 blood samples from people working and living around the construction site and sent them to the Pudong New Area Center for Disease Control and Prevention (CDC) for testing. The results showed that 36 people were positive for IgG, although none of them had symptoms.

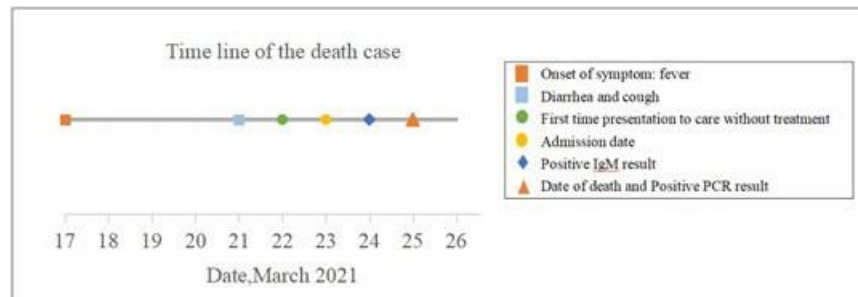


Figure 1. Time line of the HFRS death case in Shanghai, China.

5. Discussion and Conclusions

According to the results of the laboratory tests and epidemiological investigation, it was determined that this case of HFRS was caused by the decedent's contact with infected rats and their feces in the residential environment during a local outbreak. The cause of death was HFRS with multiple organ/system damage (affecting the liver, kidneys, blood and heart). The clinical features were consistent with the characteristics of HFRS and similar to those of fatal cases of HFRS reported in other regions [7-9]. The early symptoms were fever and fatigue, followed by cough and diarrhea. The patient's condition deteriorated rapidly. As the disease course progressed, typical symptoms of HFRS, such as body ecchymosis, eye conjunctival edema and bleeding, and oral coagulation, appeared. The early symptoms of HFRS are not typical; they did not cause concern in the patient himself and thus he did not see a doctor in time. The patient finally sought treatment on the 22, but his symptoms did not arouse the attention of the primary doctors

and nurses, and diagnosis and treatment were not timely. These two reasons are important factors for the high mortality associated with HFRS. The epidemic occurred in an urban-rural area of Pudong New Area. The residents in this area are mostly migrant workers with poor living conditions that are prone to rodent proliferation. Pudong New Area has an area of 1210 square kilometers and a permanent resident population of 5.567 million. There are many areas where similar incidents could occur, so rodent control and prevention education should be strengthened in relevant areas to reduce infections by hantaviruses. Moreover, we should provide health education to high-risk groups in epidemic areas, strengthen primary doctors' awareness of HFRS, detect infections in time and provide treatment as soon as possible to reduce the rates of severe illness and death. At the same time, we should strengthen rodent density monitoring and issue early warnings during rodent-borne infectious disease outbreaks. Case investigations were conducted around the construction site where the decedent had resided. Sam-

pling and testing found that the population IgG antibody carrying rate was 7.47% (36/482), which was higher than the antibody carrying rate among healthy people [10]. However, because the baseline antibody carrying status of this population is unknown, it is impossible to judge whether the high rate was caused by recent infection or because the carrying rate in high-risk groups is relatively high. In conclusion, the overall epidemic trend of HFRS in China is decreasing, but prevention and control measures in large and medium-sized cities need to be maintained [11-13]. Large cities are densely populated and have large numbers of migrant workers. Monitoring should be strengthened in areas with poor environmental conditions, such as urban-rural borders, and regular training should be conducted for primary medical institutions. Moreover, public education should be provided for high-risk groups.

6. Funding

This work is financially supported by the Shanghai Pudong New Area Joint Project: Establishment and Evaluation of COVID-19 Early Warning System under Normal Prevention and Control(PD2020D-15).

References

1. Bi Z, Formenty P B H, Roth C E. Hantavirus infection: a review and global update[J]. *Journal of infection in developing countries*. 2008; 2(1): 3-23.
2. Jonsson C B, Figueiredo L T, Vapalahti O. A global perspective on hantavirus ecology, epidemiology, and disease[J]. *Clin Microbiol Rev*. 2010; 23(2): 412-441.
3. WANG Wei-rui, XIAO Dong, ZHAO Meng-jiao. Analysis of the hot spot and epidemiologic characteristics of HFRS in Jinan in recent 15 years[J]. *Modern Preventive Medicine*. 2020; 47(24): 4435-4438.
4. Ye haofeng, Ye shuanglan, cheng xiaoning. Hemorrhagic fever with renal syndrome caused death: case report and epidemiological investigation[J]. *Chin J Viral Dis*. 2016; 6(05): 398-400.
5. Luo Xiaofeng, Zeng Weibin, Liu jie. Epidemiological investigation of a death case of severe epidemic hemorrhagic fever with renal syndrome [J]. *Preventive Medicine Tribune*. 2014; 20(05): 370-371.
6. Jing-zhong W, L Yi, C Cong. Epidemiologic characteristics of hemorrhagic fever with renal syndrome in Shenzhen, 2010-2019[J]. *China Tropical Medicine*. 2021; 21(03): 244-246.
7. Huang N, Liu N, Lu J. Peritonitis secondary to hemorrhagic fever with renal syndrome: a case report in GuangZhou China[J]. *BMC infectious diseases*. 2020; 20(1): 36.
8. Yang X, Wang C, Wu L. Hemorrhagic fever with renal syndrome with secondary hemophagocytic lymphohistiocytosis in West China: a case report[J]. *BMC Infect Dis*. 2019; 19(1): 492.
9. Ming N. Analysis of 11 deaths from hemorrhagic fever with renal syndrome[J]. *CHINA MEDICAL HERALD*. 2008; (17): 188-191.
10. China Infectious Disease Surveillance Report. 2019.
- 11.

- Kang Y, Zhou D, Tian J. Dynamics of hantavirus infections in humans and animals in Wuhan city, Hubei, China[J]. *Infection, genetics and evolution*. 2012; 12(8): 1614-1621.
12. Zheng Z, Wang P, Wang Z. The characteristics of current natural foci of hemorrhagic fever with renal syndrome in Shandong Province, China, 2012-2015[J]. *PLoS Negl Trop Dis*. 2019; 13(5): e7148.
13. Sun Yu-lan, Dou Xiang-feng, Liu Feng, Li Xu, Li Xin-yu. Genotyping and molecular tracing of one patient died from hemorrhagic fever with renal syndrome, 2020[J]. *Chinese Journal of Frontier Health and Quarantine*. 2021.