

Combined Application of Ultrasound-Guided Percutaneous Drainage and Urokinase Lavage: An Economical and Effective Treatment for Muscle Hematomas in Hemophiliacs

Liu H¹, Xu C¹, Wang W¹, Chen B², Sun J³, Feng X⁴, Zhang Y¹, Ma F¹, Du L¹, Gao Y¹ and Li Y^{1*}

¹Department of Ultrasound, Nanfang Hospital, Southern Medical University, China

²Department of Orthopaedics and Traumatology, Nanfang Hospital, Southern Medical University, China

³Department of Hematology, Nanfang Hospital, Southern Medical University, China

⁴Department of Pediatrics, Nanfang Hospital, Southern Medical University, China

*Corresponding author:

Yingjia Li,

Department of Ultrasound, Nanfang Hospital,
Southern Medical University, 1838 Guangzhou
Avenue North, Guangzhou 510515, China, Tel:
13073031713; E-mail: lyjia@smu.edu.cn

Received: 30 May 2022

Accepted: 07 Jun 2022

Published: 13 Jun 2022

J Short Name: ACMCR

Copyright:

©2022 Li Y. This is an open access article distributed under the terms of the Creative Commons Attribution License, which permits unrestricted use, distribution, and build upon your work non-commercially.

Citation:

Li Y, Combined Application of Ultrasound-Guided Percutaneous Drainage and Urokinase Lavage: An Economical and Effective Treatment for Muscle Hematomas in Hemophiliacs. Ann Clin Med Case Rep. 2022;V9(7):1-4

Keywords:

Hemophilia; Hematoma; Interventional ultrasonography; Urokinase; Percutaneous drainage

1. Abstract

Aim: An initial attempt to treat hemophilic hematoma by ultrasound-guided intratumoral drainage combined with urokinase lavage after adequate supplementation of coagulation factors.

Methods: With sufficient supplementation of coagulation factors, drainage tube was inserted into hematomas under the guidance of ultrasound. 30,000 units of urokinase were injected into the hematomas through drainage tube, the drainage tube was clamped for 6 hours and then drained for 2 hours, this process was repeated twice a day.

Results: After a 5-day and a 3-day treatment, the intermuscular hematomas in two patients basically disappeared, accompanied with compression symptoms relief. No obvious adverse reactions and serious complications were observed during the treatment and follow-up.

Conclusion: Ultrasound-guided drainage combined with urokinase lavage is a safe, effective, and minimally invasive therapeutic strategy for intermuscular hematomas in hemophiliacs, avoiding potential complications of surgical resection and limiting the cost.

2. Introduction

Hemophilia is a hereditary coagulation factor deficiency disease. Severe haemophilia patients may suffer from spontaneous or post-traumatic bleeding, of which between 10 and 25% of bleed-

ing episodes occur in muscles. If not treated in a timely manner, muscle hematoma in patients with hemophilia can lead to serious complications, such as nerve injury, osteofascial compartment syndrome, and even sepsis. The World Hemophilia Federation recommends high-dose coagulation factor replacement therapy for management of muscle hematomas in such cases [1]. However, in China and other developing countries, most patients with hemophilia do not have sufficient access to coagulation factor replacement therapy due to economic constraints, resulting in a higher incidence of muscle hematoma and poorer prognosis.

Ultrasound-guided percutaneous drainage is a fast, real-time, and well-tolerated procedure that can remove hematoma in a short time. However, for patients with hemophilia, repeated bleeding may cause organization and viscosity of hematomas, potentially lowering the success of evacuation. It is reported that urokinase can degrade the fibrin in the hematoma, making the sticky hematoma become thinner and easier to drain [2]. Hence, to improve the efficiency of drainage, we describe our initial attempt to treat muscle hematomas in hemophiliacs with ultrasound-guided percutaneous drainage and urokinase lavage after supplying enough coagulation factor.

3. Methods

Subject A, a middle-aged man, severe hemophilia A, had underwent orthopedic surgery because of severe bone destruction and

decreased muscle function of the right knee caused by repeated bleeding. Three weeks later, he felt progressive swollen in the right leg, accompanied by hyposensation from the right leg to foot dorsum. Ultrasound examination revealed a heterogeneous echomass on the lateral muscles of right calf, which was 17 * 8 * 7cm in size approximately. Based on clinical manifestation and ultrasonographic features, it was concluded that the motion disorder and sensory disturbance of the patient's right leg was caused by compression from the heterogeneous intramuscular mass. To explore the composition of the mass, a 2.4ml bolus of contrast agent (SonoVue®, Bracco, Milano, Italy) was then injected into the elbow vein. Circular hyperenhancement was observed in the periphery while no enhancement was found in the central space, suggesting that the mass was a hematoma with no obvious granulation tissue and neovascularization formed inside (Figure S1). Therefore, we tried to drain the muscular hematoma under the guidance of ultrasound. After supplementing 1500 IU of recombinant human coagulate factor VIII, a 16G puncture needle was successfully inserted into the hematoma under the guidance of ultrasound, while no hemocele could be drained out. Then a 0.038-inch wire was placed into the hematoma through the needle, followed by inserting a 12F drainage tube. However, there was still no hemocele drawn out due to viscosity of the content. Urokinase lavage was then performed based on the lack of obvious granulation tissue or neovascularization within the hematoma on CEUS. To make the viscous hemocele become diluted and easy to drain out, 30,000 IU of urokinase were dissolved in physiological saline (20 ml) and injected into the hematoma through drainage tube. The drainage tube was clamped for 6 hours in order to increase thrombolytic effect of the urokinase and then drained for 2 hours, these procedures repeated twice a day. To maintain factor VIII activity above 30% during this procedure, the patient was prescribed with prothrombin complex twice daily for 25 IU/kg. Ultrasound was adopted to monitor the change of muscle hematoma.

Subject B, a 27-year-old man with severe hemophilia A felt his right forearm swollen gradually two weeks ago. A week later, the patient felt numbness in the right thumb, index finger and middle finger, occasionally accompanied with movement disorders. Ultrasonography revealed a polycystic hematoma in the flexor of the forearm. The hematoma was located between ulna, radius, and median nerve with an approximate size about 10.5*3.5*3.2cm, compressing the median nerve, which was swollen and thickened under ultrasound detection. After injecting 2.4ml bolus of contrast agent into elbow vein, no-enhanced area was found inside the hematoma under CEUS evaluation (Figure S2). In order to relieve the compression on the median nerve, a 14F drainage tube with several side-hole was placed along the long axis of the hematoma to penetrate three main capsules under ultrasound guidance. After supplement of coagulation factor (20 IU/kg, twice a day), 20 mL saline solution containing 30,000 IU of urokinase was injected via

a drainage tube, the drainage tube was clamped for 6 hours and then drained for 2 hours (repeated twice a day).

Subject C, a 12-year-old boy with severe hemophilia A felt pain in the right hip joint accompanied with limited mobility. A wide range of heterogeneous echo mass was observed in his right iliopsoas muscle under ultrasound detection. However, since CEUS evaluation revealed an uneven hyperenhancement in the mass with scattered no-enhanced areas, suggesting that the mass might be a hematoma with abundant granulation tissue and neovascularization formed inside (Fig. S3), it was not suitable for urokinase lavage treatment in this case. Hence, the patient underwent surgery to remove the hematoma.

This study was approved by the Ethics Committee of our hospital.

Written informed consent was obtained from all patients before conventional ultrasound and CEUS examinations.

4. Results

In subject A, the hematoma gradually shrank in volume (volume is estimated based on length*width*height*0.52) under ultrasound detection during the five-day treatment. Three months later, no recurrence of the muscle hematoma was observed under ultrasound examination, and the function of the lower limbs had gradually recovered. (Fig.1)

Three days after the procedure, the hematoma in subject B basically disappeared confirmed by ultrasound. The patient gradually recovered from movement disorder and sensation disturbance in the right forearm. Four months later, no recurrence of the muscle hematoma was observed (Figure 2).

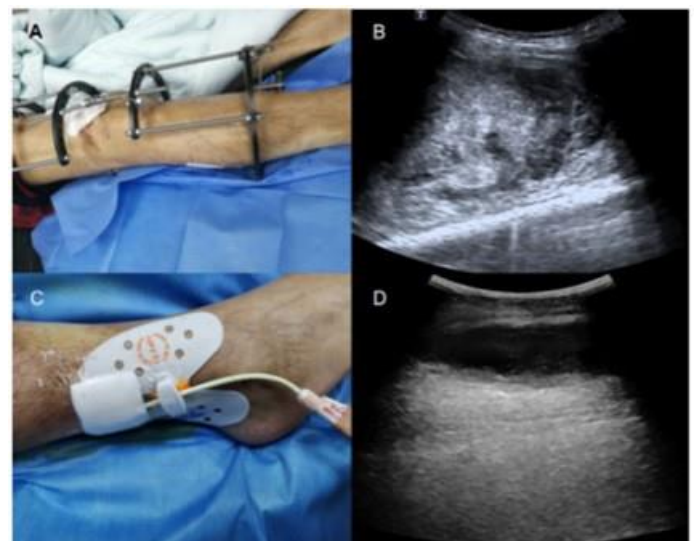


Figure 1: The bone traction device was riveted in the patient's right leg (A). Ultrasound examination revealed a heterogeneous echo mass on the lateral muscles of right calf (B). A 12F drainage tube was inserted into the hematoma (C). Five days after drainage and urokinase lavage, ultrasonography showed that the volume of hematoma decreased significantly (D).

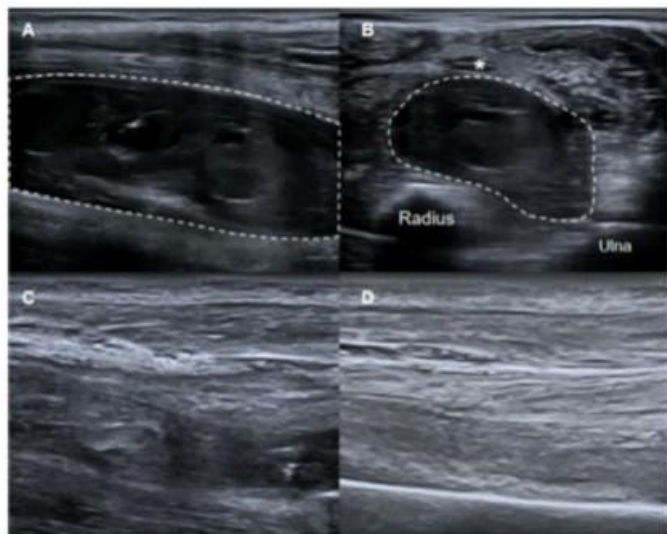


Figure 2: Ultrasound examination revealed a polycystic hematoma in the flexor of the forearm (Long Axis section of hematoma, A). The hematoma was located between median nerve (*), radius and ulna (Short Axis section of hematoma, B). Three days after drainage and urokinase lavage, ultrasonography showed that the hematoma had nearly disappeared (C). Hematoma did not recur at the 4-month follow-up after treatment (D).

5. Discussion

The most widely accepted treatment for muscular hematoma in patients with hemophilia is coagulation factor replacement therapy [1]. However, the long-term use and high dose of coagulation factors is unaffordable for many patients with hemophilia in China. In addition, this treatment does not immediately reduce the size of the hematoma. Ultrasound-guided percutaneous drainage is a low-cost, minimally invasive method for the treatment of muscle hematoma in patients with hemophilia, but its effectiveness is questionable due to few case reports that muscle hematomas caused by repeated bleeding are too viscous to be drained effectively [2-4]. With the capability of degrading fibrin in blood clots, urokinase has been reported for its effectiveness on intracavitary lavage to dissolve hematoma with viscous content such as intracranial hematoma, subdural hematoma, retroperitoneal hematoma [5-7]. Therefore, we first attempted to perform ultrasound-guided drainage combined with urokinase lavage to treat muscular hematomas in patients with hemophilia.

In subject A, about 400 IU/kg of coagulation factor in total was used during the treatment. According to the reports, for muscle hematomas of similar size, the coagulation factor dose used in replacement therapy alone was as high as 3000-4000 IU/kg, and the duration of treatment lasts for more than 20 days. Typically, such cases will undergo surgery to remove the huge hematoma. In cases of muscle hematoma causing peripheral neuropathy and loss of function, the principle of surgery is extensive fasciotomy, which will lead to massive trauma and may result in sequelae, such as scar contracture. In comparison with coagulation factor replacement therapy and surgery, ultrasound-guided drainage combined

with urokinase lavage is a feasible option in patients with hemophilia under poorer economic conditions due to its excellent performance in evacuating huge muscle hematoma in a minimally invasive manner, as well as reducing the coagulation factor dosage and treatment costs.

In subject B, although the muscle hematoma was relatively small, it was urgent to remove the hematoma in order to relieve the compression of median nerve. However, in this case, surgical operation is more traumatic and has a high risk of complications such as bleeding and infection during and after surgery. Therefore, the patient underwent the procedure of ultrasound-guided drainage combined with urokinase lavage and the hematoma shrunk significantly in a three-day treatment.

Additionally, it is worth noting that using urokinase on hematomas with abundant granulation tissue and neovascularization formed inside is inappropriate in order to avoid the risk of hemorrhage caused by the entry of urokinase into the circulatory system [5]. Therefore, the hematoma in subject C did not receive urokinase lavage treatment for potential risk of bleeding. Furthermore, urokinase can be used to dissolve acute (1-14 days) and subacute thrombosis or hematoma (15-28 days) effectively [8]. Fortunately, the formation time of hematoma in the first two cases is within four weeks. In addition, no obvious granulation tissue and neovascularization were formed inside the hematoma under CEUS evaluation, which makes it more suitable to dissolve the hematoma with urokinase.

According to some studies, local lavage of urokinase is at lower risk of inducing recurrent bleeding and hyperfibrinolysis compared with intravenous thrombolysis [9]. However, since the hemophiliacs come with poor coagulation function in most cases, it was recommended to maintain coagulation factor levels above 30% during treatment in both patients according to the perioperative guidelines for hemophilia in order to prevent rebleeding during treatment. In contrast to systemic thrombolytic therapy, which requires a high dose of urokinase to dissolve the thrombus and restore the patency of blood flow, the therapeutic goal of urokinase lavage is to reduce the viscosity of the hematoma until it can be discharged through the drainage tube. Therefore, the dosage of urokinase in the treatment process was limited with long efficient time due to safety concerns. In the first two cases, the dosage of urokinase was 60,000 IU/day, which was much lower than the dosage of systemic thrombolysis (600,000-800,000 IU/day). Under the treatment, the hematoma was drained smoothly, and there were no signs of rebleeding in the next three-month follow-up observation. These cases showed that the use of low-dose urokinase for intramuscular lavage of hematoma under conditions of coagulation factor supplementation is both safe and effective.

6. Conclusion

Ultrasound-guided drainage combined with urokinase lavage is a

minimally invasive therapeutic strategy for intermuscular hematomas in patients with hemophilia. The procedure can relieve the pressure from the hematoma immediately, shorten the treatment period, and limit the total cost with immediate results. However, further optimization is required to determine the appropriate amount and efficient time of urokinase lavage for hematomas of different sizes at various sites. In addition, there were only few cases in this study, and the follow-up time was relatively short. Further large-scale clinical studies with long-term follow-up are needed to verify the safety and efficacy of this method for treatment of muscle hematoma in patients with hemophilia.

References

1. Srivastava A, Brewer AK, Mauser-Bunschoten EP, Key NS, Kitchen S, Llinas A, et al. Guidelines for the Management of Hemophilia. *Haemophilia*. 2012; 19: 1-17.
2. SØRENSEN B, Benson GM, Bladen M, Classey S, Keeling DM, McLaughlin P, Yee TT, et al. Management of muscle haematoma in patients with severe haemophilia in an evidence-poor world. *Haemophilia*. 2012; 18(4): 598-606.
3. De la Corte-Rodriguez H, Rodriguez-Merchan EC. Treatment of muscle haematoma in haemophiliacs with special emphasis on percutaneous drainage. *Blood Coagulation & Fibrinolysis*. 2014; 25(8): 787-94.
4. Beyer R, Ingerslev J, Sørensen B. Current practice in the management of muscle haematomas in patients with severe haemophilia. *Haemophilia*. 2010; 16(6): 926-31.
5. Yeo C, Jeon W, Kim S, Kim O, Kim M. The Effectiveness of Subdural Drains Using Urokinase after Burr Hole Evacuation of Subacute Subdural Hematoma in Elderly Patients: A Preliminary Report. *Korean Journal of Neurotrauma*. 2016; 12(2): 101.
6. Zhou J, Shen D, Lu J, Hu F, Liu T. An improved electronic twist-drill craniostomy procedure with post-operative urokinase instillation in treating chronic subdural hematoma. *Clinical Neurology and Neurosurgery*. 2015; 5: 61-5.
7. Shen Z, He W, Liu D, Pan F, Li W, Han X, et al. Novel technique for the treatment of large subcapsular renal hematoma: combined use of percutaneous drainage and urokinase injection. *International Urology and Nephrology*. 2014; 46(9): 1751-5.
8. Ye K, Qin J, Yin M, Liu X, Lu X. Outcomes of Pharmacomechanical Catheter-directed Thrombolysis for Acute and Subacute Inferior Vena Cava Thrombosis: A Retrospective Evaluation in a Single Institution. *European Journal of Vascular and Endovascular Surgery: the official journal of the European Society for Vascular Surgery*. 2017; 54(4): 504-12.
9. Niizuma H, Otsuki T, Johkura H, Nakazato N, Suzuki J. CT-guided stereotactic aspiration of intracerebral hematoma--result of a hema-toma-lysis method using urokinase. *Applied Neurophysiology*. 1985; 48(1-6): 427-30.