

Prompt Treatment Prevents Poor Prognosis Of Soft Contact Lens Associated Purpureocillium Lilacinum Keratitis

Pierangela Rubino*, Andrea Garbuglia, Antonio Pio Troiano and Stefano Gandolfi

Department of Ophthalmology Unit, University Hospital of Parma, via Gramsci 14, 43126, Parma, Italy

***Corresponding author:**

Pierangela Rubino,

Department of Ophthalmology Unit, Segreteria U.O. Oculistica Azienda Ospedaliero Universitaria di Parma, Via Gramsci 14, 43126, Parma, Italy, Tel: +39 3398167304

Received Date: 03 Dec 2023

Accepted Date: 21 Dec 2023

Published Date: 26 Dec 2023

Citation:

Pierangela Rubino. Prompt Treatment Prevents Poor Prognosis Of Soft Contact Lens Associated Purpureocillium Lilacinum Keratitis. Annals of Clinical and Medical Case Reports 2023.

1. Abstract

1.1. Purpose:

To report a case of Purpureocillium lilacinum superficial keratitis treated with topical voriconazole.

1.2. Methods:

Soft contact lens associated keratitis in a 44-year-old man. Corneal culture revealed growth of Purpureocillium lilacinum only after a second corneal scraping.

1.3. Results:

The infection was well controlled by topical voriconazole and resolved within 1 month without the need of any surgical intervention.

1.4. Conclusion:

This case strengthens the efficacy of topical voriconazole in the treatment of Purpureocillium lilacinum keratitis. Anterior segment optical coherence tomography was used to detect the improvement of the anatomic condition and helped to the decision to use topical therapy alone. Purpureocillium lilacinum (previously classified as Paecilomyces lilacinus) is considered a saprophytic filamentous fungus diffusely found in various habitats frequently isolated from soil, decaying vegetation, insects, nematodes and it's used in pesticides because of its nematophagous potential [1]. The most frequent clinical manifestation of P.lilacinum infection in humans is

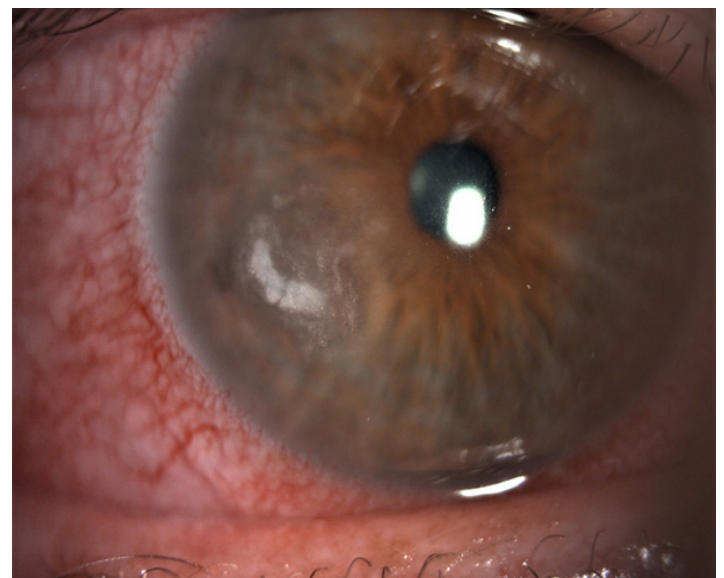
fungal keratitis often associated with the use of soft contact lenses [1–3], which is difficult to eradicate because of multiple antifungal resistance. The number of cases has been increasing in recent years, and loss of the eye is not uncommon [1,2]. This case describes the successful treatment of a soft contact lens associated keratitis, healed by only topical antimicrobial therapy alone, after early diagnosis when only the superficial stroma was involved.

Keywords:

Keratitis, Contact lenses, Purpureocillium lilacinum, Paecilomyces spp, Voriconazole

2. Case Report

A 44-year-old man was referred to our ophthalmology clinic for ocular pain, redness and photophobia in his right eye that lasted seven days prior to presentation. The patient was worried about the white lesion he noticed when looking at the mirror. He had no known history of ocular trauma, surgery or disorders, and he wore soft biweekly contact lenses for mild myopia. The patient was considered immunocompetent at the time of symptom presentation. He had no systemic medication but had undergone surgery and chemotherapy for colorectal cancer in the previous year. At first presentation BCVA (the best corrected visual acuity) was 20/20 in both eyes. Slit lamp examination demonstrated paracentral corneal infiltration at the 8 o' clock meridian approximately 3x3 mm², coupled with a whitish superficial stromal involvement and surrounding satellite infiltrations (Fig.1). There was mild hyperemia but no anterior chamber reaction.



Annals of Clinical and Medical Case Reports

Figure 1: Patient's right eye at the first visit. The photograph shows an epithelial defect and the whitish stromal involvement with satellite lesions.

The intraocular pressure was 14 mmHg (P) and dilated fundus examination revealed no alterations. Corneal scraping was performed and the patient was started on bi-hourly topical chloramphenicol/colistimethate/tetracyclines ointment and hourly topical ofloxacin 3% drops. The first corneal scraping was positive for *Staphylococcus epidermidis* and negative for fungi. Anterior segment OCT (AS-OCT) revealed corneal stromal involvement, with a maximum depth of 0.223 mm (Fig. 2).

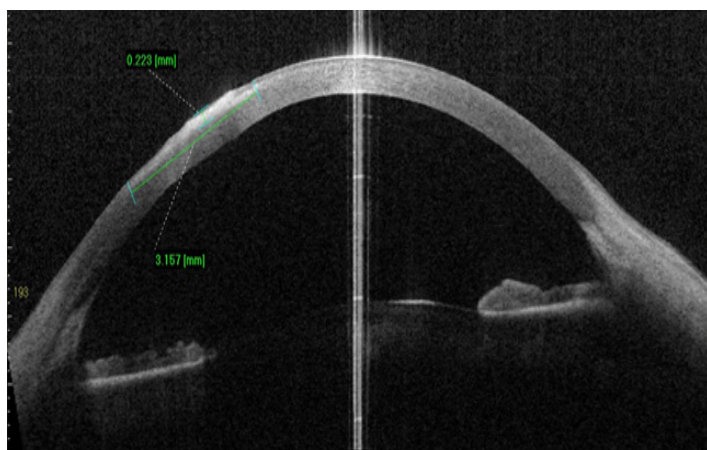


Figure 2: Anterior segment OCT shows superficial corneal involvement as an area of hyper-reflectance of 3.157 mm length, 0.223 mm thickness

On the seventh day after starting treatment there was no improvement or worsening in the clinical situation. Anterior segment examination still demonstrated a 3x3 mm² lesion with a main whitish corneal infiltrate, many small neighboring lesions, mild hyperemia, and no anterior chamber reactions. No changes were detected on the AS-OCT images. Considering these clinical findings and the poor progression of infection, the suspicion of fungal keratitis has increased. The further corneal scraping was positive for *Purpureocillium lilacinum*.

Drug susceptibility testing revealed sensitivity to isavuconazole, voriconazole and posaconazole, and resistance to fluconazole, caspofungine, itraconazole, micafungine, anidulafungine. Amphotericin B sensitivity was at the breakpoint. Topical Voriconazole 1mg/mL (MIC=0.25) hourly alone was started. After two days the patient showed improvement in symptoms and regression of the corneal infiltrates. Topical voriconazole 1mg/mL was tapered to bi-hourly treatment that was continued for ten days until the cornea completely healed. The infection responded well to treatment and fully resolved without surgical intervention. Topical voriconazole was gradually tapered six times a day for two weeks and then four times a day for other four weeks. There was no clinical recurrence at the three-month follow-up. Final BCVA was 20/20.

3. Discussion

Purpureocillium lilacinum is one of the most common saprophytic soil fungi and is often found in fruits and vegetables. This fungus has nematophagous potential and, for this reason, is now widely used as a biocontrol agent in agriculture. Previously, *P. lilacinum* was considered a contaminant; however, recent reports have shown an increasing number of primary fungal infections in humans and animals due to this microbe. Although the most common manifestation of infection is oculomycosis, typically keratitis, few cases of endophthalmitis have been described. *Paecilomyces* sp has also been reported to cause endocarditis, sinusitis, nephritis, pleural effusions, peritonitis, and cutaneous and subcutaneous infections in both immunocompetent and immunosuppressed patients, are reported. One of the main risk factors for the development of this keratitis is wearing contact lenses, as reviewed by Yuan et al. and Chen et al [2,3]. Previous studies have reported poor clinical outcomes for *P. lilacinum* keratitis: keratoplasty, recurrence of infection and loss of the affected eye are frequent [2,5–8]. The use of both systemic and topical therapies with antifungal drugs is also frequently reported in the literature.

Pei-Chen Wu et al first reported a case of superficial keratitis successfully managed with topical voriconazole 1%, then Todokoro et al reported another case of *P. lilacinum* keratitis resolved by topical voriconazole 1% [9,10]. The patient with *P. lilacinum* keratitis in our study had superficial corneal stromal infection, as confirmed by anterior segment optical coherence tomography (AS-OCT). The prompt response to treatment confirms the use of hourly topical voriconazole 1mg/mL as the first-line therapy for *P. lilacinum* keratitis with no deep stromal infiltration. We suggest to suspect fungus infection in contact lens-related keratitis with no improvement to broad-spectrum antibiotic therapy, despite the initial negative cultures for fungi. It is crucial to identify the clinical findings of fungal keratitis and eventually repeat corneal scrapings, because fungi are difficult to culture.

4. Conclusion

It is reasonable to think that a better clinical response is due to the superficial extent of the corneal infection. Furthermore, early diagnosis is a key factor in the initiation of proper care, increasing the likelihood of recovery. Our study supports the evidence of topical use of voriconazole 1mg/mL as monotherapy in superficial corneal lesions with mild stromal involvement caused by *P. lilacinum* [1,9,10].

References

1. Tayyeba K Ali, Guillermo Amescua, Darlene Miller, Leejee H Suh, Derek W Delmonte, Allister Gibbons. et al. Contact-Lens-Associated *Purpureocillium* Keratitis: Risk Factors. *Semin Microbiologic Characteristics, Clinical Course, and Outcomes. Seminars in Ophthalmology.* 2017; 32: 157-162.
2. Xiaoyong Yuan, Kirk R Wilhelmus, Alice Y Matoba, George

Annals of Clinical and Medical Case Reports

- Alexandrakis, Darlene Miller, Andrew J W Huang. Pathogenesis and Outcome of Paecilomyces Keratitis. *American Journal of Ophthalmology* 2009; 147: 691-696.e3.
3. Yen-Ting Chen, Lung-Kun Yeh, David H K Ma, Hsin-Chiung Lin, Chi-Chin Sun, Hsin-Yuan Tan. et al. Paecilomyces/Purpureocillium keratitis: A consecutive study with a case series and literature review. *Medical Mycology* 2020; 58: 293-299.
 4. Aguilar C, Pujol I, Sala J & Guarro J. Antifungal Susceptibilities of Paecilomyces Species. *Antimicrobial Agents and Chemotherapy* 1998; 42: 1601-1604.
 5. Chew R, Dorman A & Woods ML. Purpureocillium lilacinum keratitis: a case series and review of the literature. *Canadian Journal of Ophthalmology* 2016; 51: 382-385.
 6. Deng SX, Kamal KM & Hollander DA. The Use of Voriconazole in the Management of Post-Penetrating Keratoplasty Paecilomyces Keratitis. *Journal of Ocular Pharmacology and Therapeutics* 2009; 25: 175-178.
 7. Kuthan, Robert, Anna K Kurowska, Justyna Izdebska, Jacek P Szaflik, Anna Lutyńska and Ewa Swoboda-Kopeć. First Report of a Case of Ocular Infection Caused by Purpureocillium lilacinum in Poland. *Pathogens* 2021; 10: 1046.
 8. Monno R, Giovanni Alessio, Silvana Guerriero, Carmen Capolongo, Carla Calia, Luciana Fumarola et al. Paecilomyces lilacinus Keratitis in a Soft Contact Lens Wearer. *Eye & Contact Lens: Science & Clinical Practice* 2018; 44: S337-S340.
 9. Wu PC, Lai CH, Tan HY, Ma DH & Hsiao CH. The Successful Medical Treatment of a Case of Paecilomyces lilacinus Keratitis. *Cornea* 2010; 29: 357-358.
 10. Todokoro D, Yamada N, Fukuchi M & Kishi S. Topical voriconazole therapy of Purpureocillium lilacinum keratitis that occurred in disposable soft contact lens wearers. *International Ophthalmology* 2014; 34: 1159-1163.