

Abdominal Massage In Diverticular Disease Of The Colon Case Report

Piotr Burdalski*, Anna Hryniewicz and Zofia Dzięciol-Anikiej

Medical University of Białystok, Poland

Corresponding author:

Piotr Burdalski,

Medical University of Białystok, Poland

Received Date: 17 July 2024

Accepted Date: 25 July 2024

Published Date: 31 July 2024

Citation:

Piotr Burdalski. Abdominal Massage In Diverticular Disease Of The Colon Case Report. Annals of Clinical and Medical Case Reports 2024.

1. Abstract

Sigmoid diverticular disease is a disease that can significantly reduce the quality of life. This work shows the course of therapy using manual methods available to a physiotherapist. This was achieved in the presented method, and the description below is intended to show that therapy using manual methods can be used to reduce the symptoms caused by complications of diverticular disease of the large intestine.

2. Introduction

Disorders in the functioning of internal organs are the most common problem encountered by doctors of various specialties. Currently, the therapeutic approach using manual methods is becoming more and more popular. Manual therapy is one of the oldest methods used in medicine. Diverticular disease of the large intestine is a disease that can significantly reduce the comfort of life. This case report presents an attempt to find a solution to this problem using manual methods available to a physiotherapist. The presented work shows that therapy using manual methods is possible and presents the dynamics of the therapeutic process and the effects of therapy. According to the available literature, the main methods in the treatment of complications of diverticular disease of the large intestine are increasing the amount of fiber in the diet [1], treatment with probiotics [2] and surgical treatment consisting in resection of the affected part of the intestine [3-5]. This case report shows the use of left iliac fossa massage to alleviate symptoms in the course of diverticular disease of colon.

3. Background

Patient - female, 66 years old, body weight: 67 kg, 164 cm tall, BMI: 24.91, monthly net salary from 5,000 to 6,000 PLN, secondary education, lives in a large city - over 100,000 inhabitants. The patient volunteered for a study conducted as part of her studies at the Doctoral School of the Medical Teaching University of Białystok, which was approved by the local Bioethics Committee by resolution: APK.002.404.2022. The occurrence of sigmoid diverticula was confirmed for the first time in a colonoscopy in 2015, and then their occurrence was confirmed in two subsequent colonoscopies in 2018 and 2019. In the general history, the patient reported constant pain in the left lower quadrant of the abdomen with a low intensity of 3/10 VAS, which occurred 2 to 3 times a week. Additionally, the patient complained of daily constipation, which interfered with everyday functioning to a degree of 5 on a 10-point scale. The patient's constipation can be described according to the Rome IV Criteria as two alternating conditions: - during defecation there was intense and painless urgency - during defecation there is an intense painful urge, there is a feeling of incomplete evacuation in at least every fourth bowel movement. The most troublesome symptoms reported by the patient were flatulence (8/10 VAS, occurring every day) and nausea, which accompanied the patient less than once a week, but at least once every 2 weeks, which the patient perceived as significantly making life difficult - 6/10 VAS.

4. Objective

The aim of the therapy was to develop an algorithm for physiotherapeutic treatment that could constitute an alternative for patients with diverticular disease of the large intestine who do not respond to other forms of therapy. The therapy involved massage of the left iliac fossa in 6 directions proposed by the researcher, shown in Figure 1.

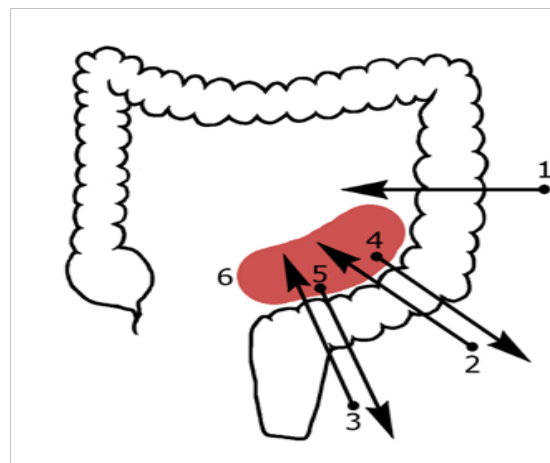


Figure 1: Directions of massage performed by a physiotherapist

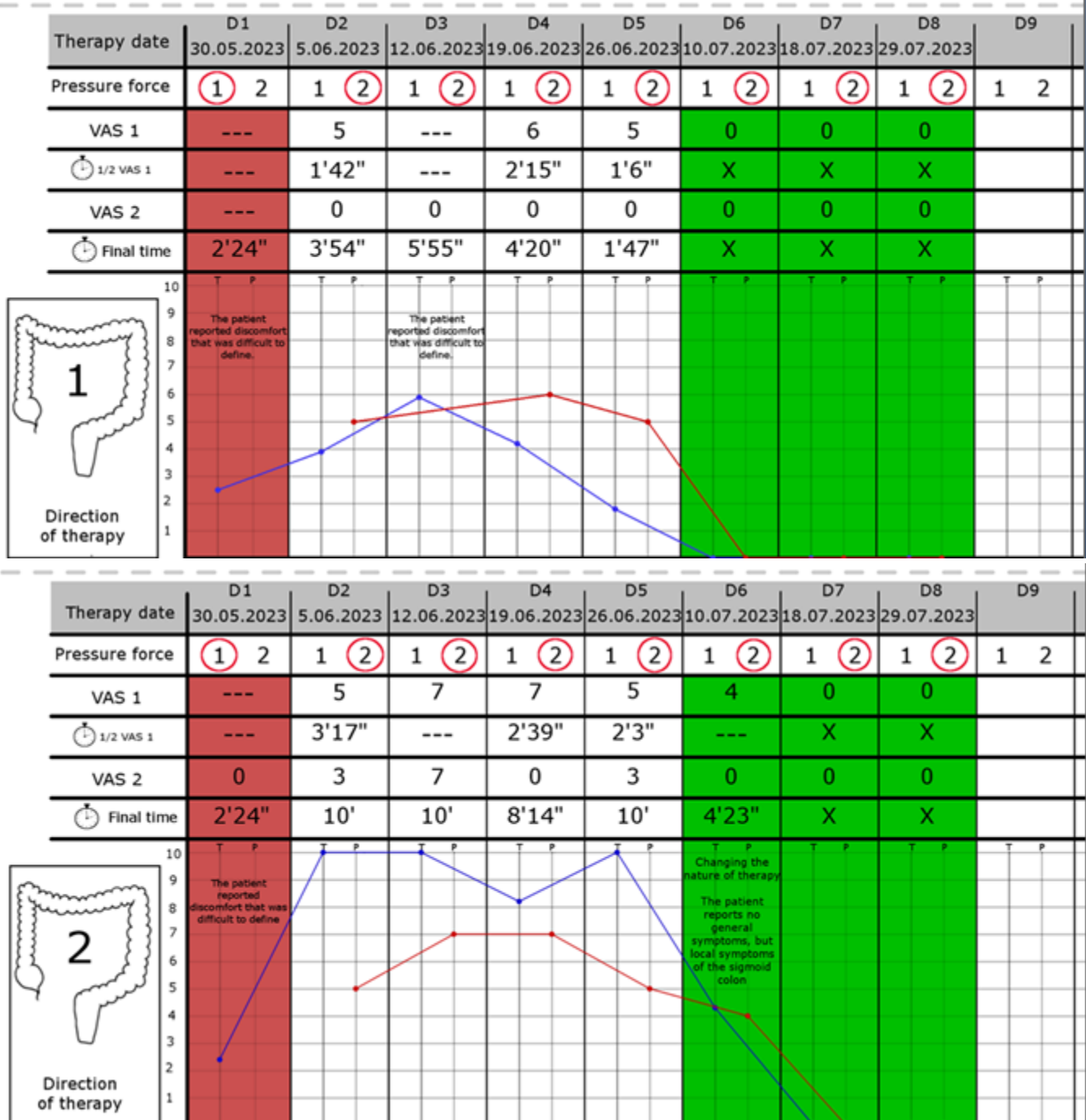
Annals of Clinical and Medical Case Reports

5. Case report

Therapy day 1 - The patient allowed the therapist to work only on superficial tissues, it was not possible to delve into the abdominal tissues due to the large amount of gas and great tenderness (positive Blumberg's sign in the left iliac fossa). In the direction of massage 1 and 2, it was impossible to determine the level of discomfort on the VAS scale - the patient reported severe discomfort that she was unable to define - the pressure force was not increased during the first day of therapy. The

symptoms have changed: In direction 1, a feeling of relaxation appeared after the total working time - 2 minutes 24 seconds. In direction 2, it was possible to reduce the symptoms to the level of 0 VAS in 2 minutes and 24 seconds. In directions 3 to 5, it was possible to reduce the symptoms of superficial tissues to the level of 0 VAS in about 2 minutes for each direction - information included in Table 1 - Dynamics of the therapeutic process - highlighted in red.

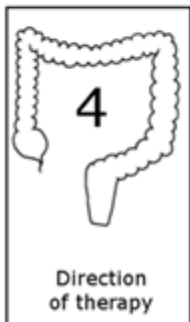
Table 1 - Dynamics of the treatment process



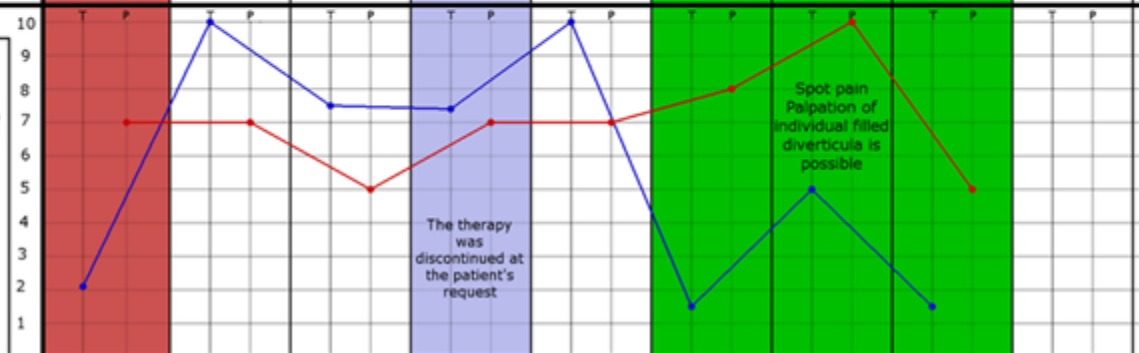
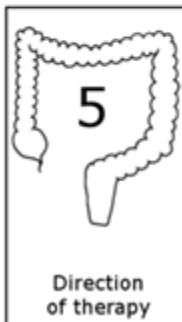
Annals of Clinical and Medical Case Reports

	D1	D2	D3	D4	D5	D6	D7	D8	D9
Therapy date	30.05.2023	5.06.2023	12.06.2023	19.06.2023	26.06.2023	10.07.2023	18.07.2023	29.07.2023	
Pressure force	1 2	1 2	1 2	1 2	1 2	1 2	1 2	1 2	1 2
VAS 1	6	6	7	7	5	4	0	0	
🕒 1/2 VAS 1	1'20"	4'1"	4'45"	1'48"	---	---	X	X	
VAS 2	0	0	3	0	5	0	0	0	
🕒 Final time	1'59"	5'51"	10'	7'7"	10'	4'40"	X	X	

	D1	D2	D3	D4	D5	D6	D7	D8	D9
Therapy date	30.05.2023	5.06.2023	12.06.2023	19.06.2023	26.06.2023	10.07.2023	18.07.2023	29.07.2023	
Pressure force	1 2	1 2	1 2	1 2	1 2	1 2	1 2	1 2	1 2
VAS 1	4	7	8	8	5	0	7	0	
🕒 1/2 VAS 1	49"	4'21"	3'58"	---	5'47"	---	---	X	
VAS 2	0	0	0	6	2	---	7	0	
🕒 Final time	1'47"	6'29"	9'27"	6'50"	10'	---	3'30"	X	











	D1	D2	D3	D4	D5	D6	D7	D8	D9
Therapy date	30.05.2023	5.06.2023	12.06.2023	19.06.2023	26.06.2023	10.07.2023	18.07.2023	29.07.2023	
Pressure force	1 2	1 2	1 2	1 2	1 2	1 2	1 2	1 2	1 2
VAS 1	7	7	5	7	7	8	10	5	
🕒 1/2 VAS 1	1'1"	3'59"	4'9"	3'19"	2'40"	30"	---	47"	
VAS 2	0	3	0	4	2	0	0	0	
🕒 Final time	2'17"	10'	7'40"	7'30"	10'	1'33"	5'	1'28"	



Annals of Clinical and Medical Case Reports

	D1	D2	D3	D4	D5	D6	D7	D8	D9
Therapy date	30.05.2023	5.06.2023	12.06.2023	19.06.2023	26.06.2023	10.07.2023	18.07.2023	29.07.2023	
Pressure force	1 2	1 2	1 2	1 2	1 2	1 2	1 2	1 2	1 2
VAS 1				5	5	4	6	0	
1/2 VAS 1				2'12"	6'19"	1'24"	1'6"	X	
VAS 2				0	3	0	0	X	
Final time				5'17"	10'	2'28"	2'25"	X	
	10								

Legend

-  - Backlight on the first day - the symptoms are the most severe
-  - Day 4 backlight - therapy interrupted in directions 4 and 5 - direction 6 added - therapy of the central part
-  - The period in which the nature of the therapy changed, possible palpation of the sigmoid colon and therapy of individual painful points in the course of the intestine
-  - Determination of the end time of therapy
-  - Determination of the level of initial pain reported by the patient
- VAS 1 - Determination of first pain level
- VAS 2 - Determination of end pain level
-  1/2 VAS 1 - Determination of the half-time of resolution of initial symptoms
-  Final time - Determination of the time of complete resolution of the symptoms
-  - 0 - 10 VAS / T - Time / P - Pain

Day 2 - it was possible to move on to the second degree of pressure therapy, i.e. deep palpation. Due to the fact that this is the 2nd day of therapy and the large intestine filling with gases, it was possible to slightly exceed the tissue resistance.

Day 3 - in direction 1, indescribable discomfort appeared again, which disappeared within 5 minutes and 55 seconds. It was difficult to estimate the half-time of the symptoms disappearing. Additionally, and more importantly, severe pain occurred in all directions of the massage, which did not subside even after the maximum therapy time proposed by the researcher (maximum therapy time - 10 minutes). A positive symptom during the physical examination was the visible rib arches and the patient's abdomen was less filled with gas. This allowed for greater force to be applied toward the sigmoid colon. With subsequent days of therapy,

it was possible to delve deeper into the tissues.

Day 4 - during the massage in directions 4 and 5, pain occurred when delving into the tissues. Due to the fact that the symptoms decreased when the large intestine was supported and increased when the pressure was directed towards the navel, differentiation with the small intestine was performed - direction 6. For this purpose, a massage of the central part of the abdomen was performed, mainly in the part where the large intestine affected by diverticula borders the loops of the small intestine. Positive differentiation result - massage in direction 6 was used until the end of the therapy. The remaining directions of therapy remained at a similar level as in the previous days, but the level of tissues penetration was greater.

Day 5 - The patient reported the occurrence of fecal stones in the excreted content after therapy on day 4, and the consistency of the stool changed to a more uniform one. Additionally, constipation changed its character significantly - the symptoms described by the Rome IV Criteria as "painful urge and feeling of incomplete evacuation" disappeared and did not return until the end of the therapy. The flatulence changed - the patient assessed this complaint as 2/10 VAS, occurring every day (previously 8/10 VAS, occurring every day). The patient noticed that the clothes she wore were much less tight on her belly. During the therapy, the patient did not take any actions aimed at reducing body weight. On physical examination - the abdomen was soft, painless, and compared to the first examination, the rib arches were clearly visible in a relaxed position.

Day 6 - The patient reported that bowel movements were carried out without painful urge, the patient reported significant improvement. In direction 1, there was no pain at maximum pressure (end of tissue resistance). In direction 4, great pain was found, previously absent, in the place where the range of pushing during the massage ended - differentiation was made with the iliopsoas muscle, iliac part and sigmoid colon - positive differentiation result. Muscle therapy reduced the symptoms. During palpation of the sigmoid colon and work in 5 basic directions, the symptoms were less than in the previous days and disappeared after a shorter time. From day 6, there is a noticeable downward trend in the symptoms - much greater force can be used in therapy, the abdomen is soft, and there is no bloating.

Day 7 - during this visit, the change in the nature of work from general

Annals of Clinical and Medical Case Reports

to specific was confirmed. No discomfort during general abdominal palpation. The patient reported that the “Bloating” symptom had disappeared - VAS 0. When trying to perform therapy in the five directions that were used so far, the patient reported pain in specific places, and not in a larger area, as was the case before. On that day, the patient reported that she had not performed additional activities aimed at improving intestinal function for last 2 weeks - the patient stopped drinking the cabbage juice she had previously used. Additionally, after the 6th day of therapy, the patient reported the excretion of fecal stones, which corresponds to the impression that the therapist and the patient had during the therapy on day 6, related to the emptying of the diverticula of residual content (the impression of the contents of the diverticulum being clearly pushed into the intestinal lumen in 2 places).

Day 8 – no pain in 4 out of 5 main massage directions and no pain in the central section. The pain appeared during direction 5 therapy with an intensity of 5/10 VAS and disappeared after 1 minute 28 seconds. Day 8 was the last day of therapy due to the lack of serious symptoms in the abdominal cavity and the lack of pain in most massage directions.

6. Follow Up

At the time of writing the study, the patient’s condition was checked via teleconsultation. On the day of the consultation, the patient did not report any previous ailments, only those that occurred sporadically after a specific meal (fatty or heavily fried food or as a result of overeating).

“Flatulence”: Start of therapy 8/10 VAS

- end of therapy 0/10 VAS

- no recurrence at the time of follow-up

“Constipation/difficulty passing stools” - the patient reported that there were no disturbing symptoms during defecation. No additional pushing is needed, no pain during defecation, no feeling of incomplete evacuation. Abdominal pain in the left iliac fossa - has not occurred since the end of therapy. 100 days after the last visit, the above-mentioned symptoms have not returned - the patient feels good and does not report any problems. The patient’s condition is still being monitored. After 7 months – the patient reported slightly severe constipation In the 8th month - the patient reported a recurrence of the symptoms - pain, constipation and flatulence returned - in the patient’s opinion, the symptoms returned after a series of family receptions where difficult to digest foods were served.

7. Discussion

There are many studies in the literature regarding various forms of abdominal massage and its use in various diseases. In the author’s opinion, the most refined study is the analysis presented by Gaofeng et al., which took into account publications from 1990 to 2021 dealing with this form of therapy. Of the 107 publications analyzed, 53 of which dealt with digestive system disorders in adults, none dealt with the use of abdominal massage in diverticular disease of the colon [6].

8. Conclusion

1. Manual therapy may be used in diverticular disease of the large intestine
2. Manual therapy may provide long-term improvement in the patient’s condition by removing the cause of inflammation (mechanical unblocking of the diverticulum - symptom reported by the patient: excretion of fecal stones on the day of therapy after the massage, followed by normal consistency of the excreted contents in the following days)
3. It opens the way to further research in this direction and allows to algorithmize the treatment process, shows how to parameterize and standardize the therapeutic process.

References

1. Aldoori WH, Giovannucci EL, Rockett HR, Sampson L, Rimm EB, Willett WC. A prospective study of dietary fiber types and symptomatic diverticular disease in men. *J. Nutr.* 1998; 128: 714-719.
2. Edith Lahner, Cristina Bellisario, Cesare Hassan, Angelo Zullo, Gianluca Esposito, Bruno Anibale Probiotics in the treatment of diverticular disease. A systematic review. *J Gastrointest Liver Dis;* 2016; 25(1):79-86.
3. Stollman N, Smalley W, Hirano I. AGA Institute Clinical Guidelines Committee. American Gastroenterological Association Institute: Guideline on the management of acute diverticulitis. *Gastroenterology.* 2015; 149: 1944-1949.
4. Kruis W, Germer ChT, Leifeld L. Diverticular Disease: guidelines of the German Society for Gastroenterology, digestive and metabolic diseases and the German Society for General and Visceral Surgery. *Digestion* 2014;90:190-207.
5. Binda GA, Cuomo R, Laghi A, Nascimbeni R, Serventi A, Bellini D, Gervaz P, Annibale B. Practice parameters for the treatment of colonic diverticular disease: Italian Society of Colon and Rectal Surgery (SICCR) guidelines. *Tech Coloproctol* 2015; 19:615-626.
6. Gaofeng Wang, Zepeng Zhang, Jiabao Sun, Xiangyan Li, Yunjie Chu, Daqing Zhao, et al. Abdominal massage: a Review of clinical and experimental studies from 1990 to 2021. *Complementary Therapies in Medicine.* 2022; 70: 102861.